

Cutaneous infection by *Alternaria infectoria* in a liver transplant recipient : a case report

E. Coussens¹, S. Rogge², M. Haspeslagh³, A. Geerts¹, X. Verhelst¹, H. Van Vlierberghe¹, R.I. Troisi⁴, I. Colle¹

(1) Department of Hepatology and Gastroenterology, (3) Department of Dermatology, (4) Department of General and Hepatobiliary Surgery, Liver Transplantation, Ghent University Hospital, Ghent, Belgium ; (2) Department of Gastroenterology, AZ Sint-Lucas Hospital, Ghent, Belgium.

Abstract

We report the case of a 65-year-old man who developed multiple crusty ulcerative skin lesions on both lower extremities six months after liver transplantation. The causative pathogen was identified as *Alternaria Infectoria*, an opportunistic fungal agent. The patient was successfully treated with fluconazole for 27 weeks, with complete regression of the lesions. Due to the lack of well-designed clinical studies it is difficult to determine the best treatment course regarding solid organ transplant recipients presenting with invasive fungal infections. And for now, the clinician must lean upon case-reports or retrospective analyses to compose the most suited therapy for his patient. Based upon literature, it seems that the combination of a broad spectrum azole and reducing the dose of immunosuppressive drugs is the cornerstone of treating invasive fungal infections in solid organ transplant patients. (*Acta gastroenterol. belg.*, 2014, 77, 256-258).

Introduction

Skin lesions are common in solid organ transplant recipients and clinicians should be aware of the fact that deep cutaneous mycotic infections in these patients can be life threatening. Therefore, early diagnosis and accurate treatment are of vital importance. We report the case of a 65-year-old male liver transplant recipient who spontaneously developed purple red nodules with a crusty surface on the left thigh, the posterior side of the left ankle and on the right knee.

Case presentation

The patient underwent an orthotopic liver transplantation from a non-heart-beating donor in May 2009 for a hepatocellular carcinoma secondary to an alcoholic cirrhosis. There was no history of rejection and the patient was taking tacrolimus 8 mg daily as long-term immunosuppressive drug with through levels around 10 ng/mL. In addition he was treated with ursodeoxycholic acid, calcium kayexalate, allopurinol and calcium/vitamin D supplements.

Six months after transplantation he developed multiple well delineated painless erythematous nodules (0.5-1 cm) covered with a yellowish crust, on both lower extremities (Fig. 1). There was no history of trauma or skin laceration and there was no fever. The clinical condition of the patient was otherwise good and there were no laboratory abnormalities. A punch biopsy was performed and routine microscopy showed histological

changes suggestive for infectious dermatitis, namely irregular epithelial hyperplasia with necrosis and micro-abcdated granulomatous inflammation (Fig. 2). There were no signs of dysplasia or malignancy. Deep mycological cultures of the skin lesion biopsy showed mycelium threads, prognostic for a fungal infection, but the causative agent at first could not be cultured. Periodic acid-Shiff staining after amylase staining confirmed the presence of mycotic buds. Mucicarmine staining and Acian Blue techniques were performed and by their negativity excluded Cryptococcosis. The histological picture was also not compatible with histoplasmosis, since this fungal agent normally remains intracytoplasmatic. Finally, in a second sample *Alternaria infectoria* was cultured from part of the crustae.

Once the diagnosis of a deep cutaneous mycosis was established, a treatment with fluconazole (200 mg bid) was started with close follow-up of tacrolimus through levels around 8 ng/mL. The dose of tacrolimus was reduced to 1 mg and 0.5 mg alternating due to interaction with fluconazole at CYP3A4 level. Nineteen weeks after the start of the treatment the skin lesions were almost completely healed (Fig. 1). The fluconazole was stopped after twenty-seven weeks of treatment.

Discussion

Alternaria is a genus of ascomycete fungi. This species is known as a major plant and fruit pathogen but it is also an opportunistic fungal infectum in patients with immunosuppression or debilitating diseases such as diabetes or acquired immune deficiency syndrome (AIDS). Older age and viral infections like cytomegalovirus (CMV) are additional risk factors (1,9,11). In this clinical setting, this type of invasive fungal infections is associated with high morbidity and mortality rates. In our patient, CMV polymerase chain reaction (PCR) tests were performed on a regular basis and always remained negative. During the early post-transplant period the risk of invasive fungal infections is higher, because then the

Correspondence to : Coussens Emma, Elfde Julilaan 14, 8791 Beveren-Leie, Belgium. E-mail : emma.coussens@ugent.be

Submission date : 28/04/2013

Acceptance date : 28/04/2013

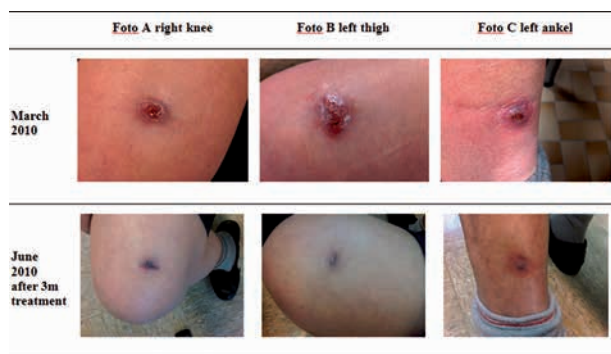


Fig. 1. — Skin lesions before treatment in March 2010 and after 3 months of treatment with fluconazole in June 2010 (A) on the right knee, (B) on the left thigh, (C) on the left ankle.

grade of immunosuppression is greatest (10). Pereiro *et al.* suggested in their review that patients receiving tacrolimus are at a higher risk for deep cutaneous mould infections and that these infections are more severe and therapy-resistant than in patients treated with other types of immunosuppression (12).

In a retrospective cohort study of 3293 organ transplant patients 22 patients (0.7%) developed a primary deep cutaneous mycosis. In this study, simultaneous treatment with corticosteroids appeared to be an important co-factor, possibly because these drugs cause cutaneous fragility. In most of the patients there was a history of contact with animals and plants. In this cohort three patients died of systemic dissemination of the infection (6).

The genus *Alternaria* is one of about 30 fungal genera that can cause invasive fungal disease caused by darkly pigmented moulds, called phaeohyphomycosis. Microscopically we find a typical golden brown coloring of the cell walls and fungal hyphae caused by melanin pigments (8,10). Our patient expressed a dermal type of human alternariosis, where pigmented hyphae and open round bodies are surrounded by granulomatous inflammation (11). Since there is no simple serologic or antigen test to detect phaeohyphomycosis in blood or tissue and a superficial swab does not allow distinguishing between an environmental contamination and a true infection, the diagnosis has to be established by performing a biopsy for histologic examination and culture (8).

The clinical presentation may range from local skin lesions to invasive and disseminated infection, although the latter is rare (4,10). The cutaneous manifestations include erythematous maculae or papules, ulcerating plaques as well as vegetating or nodular lesions. The arms or the legs are the most common sites of infections. These often painless lesions should be distinguished from neoplastic diseases (Kaposi) and other fungal (sporothrichosis) and parasitic infections (leishmaniasis) (2,3,5).

Unfortunately, there are no evidence based recommendations for the management of invasive fungal infections in transplant recipients. Most of the lesions are

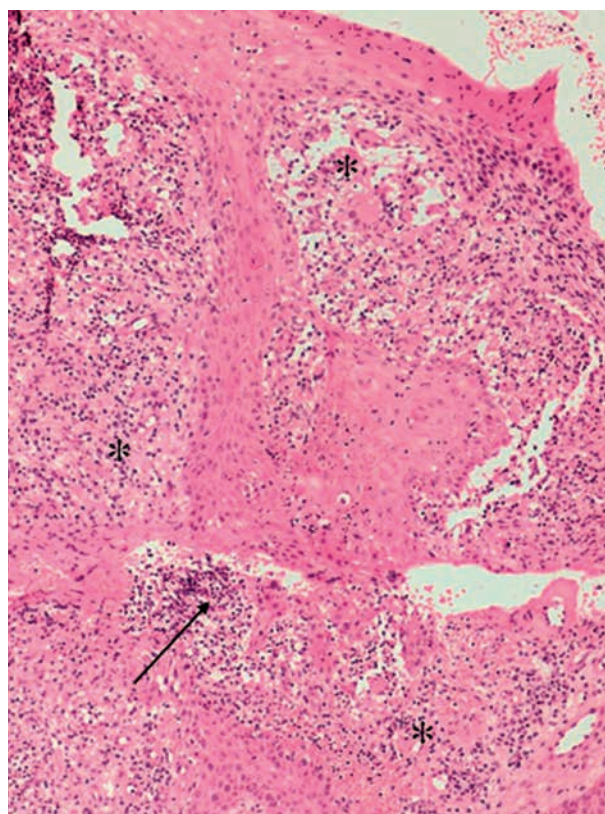


Fig. 2. — Micro-abcidating, granulomatous inflammation (*) with secondary epithelial hyperplasia (→). H&E $\times 20$.

susceptible to triazoles, including itraconazole and voriconazole. Therefore, empirical and long-term anti-fungal therapy based on itraconazole is considered as the cornerstone of treatment of phaeohyphomycosis (2,7,8,11). Vermeire *et al.* advocate surgery in well delineated lesions. In comparison to our patient, cure was also achieved in the second case of Vermeire *et al.* This case demonstrates a 71-year-old male renal allograft recipient also treated with Tacrolimus. The patient developed simultaneous lesions as in our patient and the pathogen was identified as *Curvularia* spp. The patient was able to be cured by the use of Itraconazole capsules 200mg bid and the tacrolimus dose was reduced from 1mg bid to 0.5mg every third day. Our case combined with the case demonstrated by Vermeire *et al.* both indicate that healing of fungal lesions in transplant patients can be achieved by the use of broad spectrum antifungal treatment (8). Vieira *et al.* reported a case study in which the patient presented with similar lesions due to *Alternaria Infectoria* as well. Here, the patient was able to be cured solely by decreasing immunosuppression, no concomitant surgery was performed and no antifungal therapy was administered (9).

Broad spectrum azoles are strong CYP3A4/5 inhibitors causing major drug-drug interactions with several agents such as tacrolimus and ciclosporine resulting in increased through levels and side effects, therefore we reduced the immunosuppressive therapy to a minimal level. It is of utmost importance to closely observe and

monitor tacrolimus and ciclosporin levels as to be clinically cautious for signs of toxicity. Strict monitoring must also be maintained after discontinuation of azole therapy because this could result in underexposure of immunosuppressant agents inducing an elevated risk of acute graft rejection (8,10).

Conclusion

Since there is no simple serologic or antigen test to detect phaeohyphomycosis in blood or tissue, only performing a punch biopsy for histologic examination and deep mycological culture of the lesions can lead to the correct diagnosis.

In literature, there are no unambiguous guidelines regarding treatment of these lesions. Based upon this study and several articles we can summarize that long-term anti-fungal therapy based upon broad spectrum azoles, with close monitoring of tacrolimus and ciclosporin levels, can be seen as the cornerstone of treatment of deep cutaneous mycotic infections in solid organ transplant recipients. Surgical excision can be a sufficient treatment option in patients with small and well delineated solitary lesions, when systemic involvement has been excluded.

References

1. GALLELLI B. *et al.* Skin infection due to *Alternaria* species in kidney allograft recipients : report of a new case and review of the literature. *J. Nephrol.*, 2006, **19** : 688-672.
2. DUBOIS D. *et al.* Cutaneous phaeohyphomycosis due to *Alternaria* infectoria. *Mycopathologia*, 2005, **160** : 117-123.
3. SEGNER S. *et al.* Cutaneous infection by *Alternaria* infectoria in a renal transplant patient. *Transplant Infectious Disease*, 2009, **11** : 330-332.
4. HALABY T. *et al.* Phaeohyphomycosis caused by *Alternaria* infectoria. *Br. J. Dermatol.*, 2001, **145** : 1952-1955.
5. VIEIRA R. *et al.* Cutaneous alternariosis in a liver transplant recipient. *Rev. Iberoam. Micol.*, 2006, **23** : 107-109.
6. TESSARI G. *et al.* Incidence and clinical predictors of primary opportunistic deep cutaneous mycoses in solid organ transplant recipients : a multicenter cohort study. *Clin. Transplant.*, 2010, **24** : 328-333.
7. NULENS E. *et al.* *Alternaria* infectoria phaeohyphomycosis in a renal transplant patient. *Med. Mycol.*, 2006, **44** : 379-382.
8. VERMEIRE S. *et al.* Cutaneous phaeohyphomycosis in renal allograft recipients : report of 2 cases and review of the literature. *Diagnostic Microbiology and Infectious Disease*, 2010, **68** : 177-180.
9. VIEIRA R. *et al.* Cutaneous alternariosis in a liver transplant recipient. *Rev. Iberoam. Micol.*, 2006, **23** : 107-109.
10. GABARDI S. *et al.* Invasive fungal infections and antifungal therapies in solid organ transplant recipients. *Transplant. International*, 2007, ISSN 0934-0874.
11. ACLAND K. *et al.* Cutaneous infection with *Alternaria* *Alternata* complicating immunosuppression : successful treatment with itraconazole. *British Journal of Dermatology*, 1998, **138** : 354-356.
12. PEREIRO M. *et al.* Cutaneous infection caused by *Alternaria* in patients receiving tacrolimus. *Med. Mycol.*, 2004, **42** : 277-82.